



INTISARI SAINS MEDIS

Published by Intisari Sains Medis

Refractive lens exchange on keratoconus patient: a case report



CrossMark

Ivane Jessica Buddyman*, Cokorda Istri Dewiyani Pemayun,
Ariesanti Tri Handayani

Ophthalmology Department, Faculty of Medicine,
Universitas Udayana, Sanglah General Hospital,
Denpasar Bali

*Corresponding to:

Ivane Jessica Buddyman; Ophthalmology
Department, Faculty of Medicine, Universitas
Udayana, Sanglah Hospital Denpasar Bali.
anne_0810009@yahoo.com

Received: 2021-02-14

Accepted: 2021-04-12

Published: 2021-04-30

ABSTRACT

Introduction: Keratoconus is a vision disorder that occurs when the cornea becomes thin and irregularly (cone) shaped. Instead of being focused correctly on the retina, this abnormal shape causes the light entering the eye to improperly refract and manifested as a distortion of vision. Refractive Lens Exchange is one type of Invasive therapy in Keratoconus. Here we describe a case of Keratoconus managed by the Refractive Lens Exchange procedure in our Center.

Case Description: A male, 25 years old, visited the clinic due to blurry vision since ten years ago. Every six months or a year, he needs to adjust his lens power. Ophthalmology examination found visual acuity in the right eye was 2/60 PH 6/60, and if using S-9.00, visual acuity improved to 6/30. Meanwhile, visual acuity in the left eye was 1/60 PH 6/60 and if using S-11.75,

visual acuity improved to 6/48. Corneal topography supports the finding of Keratoconus. Management for this patient was Refractive Lens Exchange + Intraocular Lens + Capsular Tension Ring. Initially, This advised was differ from the patient expectation, as he wanted a LASIK procedure. An important reminder was given, that Keratoconus is contraindicated for LASIK and any corneal surface ablation procedure. After series of procedure, the VA of the right eye was 6/15 PH 6/6, with C - 4.00 x 180° VA became 6/6. VA left eye was 6/18 PH 6/9, with C - 4.00 x 180° VA became 6/9. Binocular vision was 6/6. For near vision, S +3.00 was added for both eyes.

Conclusions: Refractive Lens Exchange + Intraocular lens implantation is effective and safe procedures to treat high myopia in keratoconus cornea.

Keywords: keratoconus, Refractive Lens Exchange, Intraocular Lens, Capsular Tension Ring, LASIK

Cite This Article: Buddyman, I.J., Pematun, C.I.D., Handayani, A.T. 2021. Refractive lens exchange on keratoconus patient: a case report. *Intisari Sains Medis* 12(1): 290-293. DOI: [10.15562/ism.v12i1.959](https://doi.org/10.15562/ism.v12i1.959)

INTRODUCTION

Keratoconus is a common disorder in which the central or paracentral cornea undergoes progressive thinning and protrusion, resulting in a cone-shaped cornea leading to irregular astigmatism and visual deterioration. Keratoconus characteristically a bilateral but asymmetric progressive disease.^{1,2}

Keratoconus is a common disorder, with an incidence rate about 1 every 2000 person. Onset usually occurs during puberty, and the progression rate is at a peak in young age. Progression typically slows in the fourth decade of life and is unusual after the age of 40 years.³ Keratoconus occurs in both genders. No gender predominance has been reported previously, whereas recent reports have

suggested a higher prevalence among male patients.² The etiology of Keratoconus is multifactorial. Keratoconus can be associated with family history, ethnicity (Asian and Arabian), mechanical factors (eye rubbing, floppy eyelid), ocular allergy. It can also be associated with systemic diseases, including atopic disease, Down syndrome, Ehlers-Danlos syndrome, Osteogenesis Imperfecta, Sleep Apnea, and Mitral valve prolapse.^{1,2}

Disease progression is manifested by a significant loss of visual acuity, which cannot be compensated with spectacles. Visual acuity of 6/6 or a close to is difficult to achieve with the increasing against-the-rule astigmatism. Additionally, Keratometry readings are commonly abnormal.³ Early detection for keratoconus

could be achieved with corneal topography and Scheimpflug imaging or anterior segment Optical Coherence Tomography. Advanced keratoconus can be diagnosed using only slit-lamp and manual keratometry, but for more sensitive analysis, corneal topography and corneal pachymetry should still be used.^{4,5}

Keratoconus is considered a contraindication for LASIK and corneal surface ablation. Therefore, a complete examination of the eyes is a must to establish a correct diagnosis before attempting a therapy. Inappropriate therapy on Keratoconus can cause more severe and permanent visual disturbances. Thus, it is obvious that a proper diagnosis is needed to provide satisfactory therapeutic results.^{1,5,6}

The complication of Keratoconus is vision loss which occurs mainly due to corneal protrusions or corneal scarring. Corneal thinning usually occurs in the center of the cornea as well as in the infratemporal cornea. Advanced keratoconus can develop corneal hydrops, which can cause corneal scars.⁵

This article aimed to increase knowledge in making a diagnosis, examining, and considering the management of Keratoconus cases to produce excellent and optimal visual acuity resolution by retelling our experience.

CASE DESCRIPTION

A male patient, 25 years old, came to the Ophthalmology Polyclinic with a

complaint of blurred vision in both eyes since ten years ago. At that time, he prescribed a pair of glass with a power of S -2.50. Every six months or a year, the power of the glasses changes. Since two years ago, the patient used glasses with different power, the right was S -11.00 and the left was S -16.00. However, the patient felt that his vision was still blurry and uncomfortable, so the patient asked and expressed his willingness about the LASIK procedure.

The patient was office workers who sat in front of a computer screen for about 8-10 hours/day. The patient admitted that he often rubbed his eyes, was allergic to dust and often sneezed. Family history of wearing glasses, trauma, contact lens use, the systemic disease was denied.

Ophthalmology examination found visual acuity (VA) of the right eye was 2/60 Pinhole (PH) 6/60, and if using S-9.00, the VA became 6/30. The VA of the left eye was 1/60 with PH increase to 6/60, and if using S -11.75, the VA becomes 6/48. Corneal examination of both eyes revealed cone-shaped cornea (Keratoconus), photographed in Figure 1. Other than that, the other anterior segments of both eyes were within normal limits. Fundus examination of both eyes revealed well-defined, rounded papillae of the second cranial nerve (N.II), cup disc ratio was 0.3, retinal lattice degeneration, macular reflex (+).

The corneal topography of the right eye was steep K 56.38 D @ 92, Flat K 52.95 D @ 2, Astigmatism 3.43 D, Q - 0.82, Shape factor 0.82, pupil diameter 7.1 mm, Axial I - S 2.98 D. On the left eye, the results were steep K 60.89 D @ 76, Flat K 55.65 D @ 166, Astigmatism 5.24 D, Q - 0.77, Shape factor 0.77, pupil diameter 6.9 mm, Axial I - S 6.65D. The right eye's specular results showed a mean central corneal thickness (CCT) of 499, while the mean CCT of the left eye was 424. Anterior segment optical coherence tomography (OCT) of the right eye obtained an angle formed between the cornea and the iris at temporal was 46° and at the nasal was 430°, while in the left eye at the temporal was 36° and at the nasal was 39° (Figure 2).

The patient was diagnosed with High Myopia + Keratoconus, both the right and left eye. The patient was planned to undergo Refractive Lens Exchange (RLE) + Intraocular Lens (IOL) + Capsular Tension Ring (CTR). The patient was fitted for IOLs with the barret formula. The axial length of the right eye was 23.23, K1 53.25 D, K2 54.25 D, IOL + 7.00 D; axial length left eye was 23.59, K1 53.75 D, K2 55.25 D, IOL + 4.00 D.

The first day after the procedure (RLE + IOL + CTR), VA of the right eye was 6/9 and VA of left eye 6/45 PH 6/18. The conjunctiva both eyes showed subconjunctival bleeding, cornea showed corneal edema and Descemet fold, and IOL in place. A week and a month after surgery, the visual acuity in the right eye was 6/6. The visual acuity left eye was 6/45 PH 6/18, anterior segment of both eyes within normal limits, IOL (+).

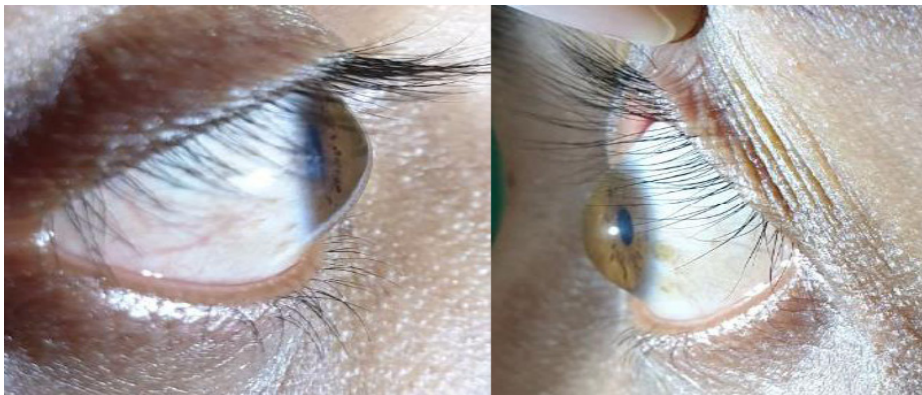

Figure 1. Preoperative lateral eye view.

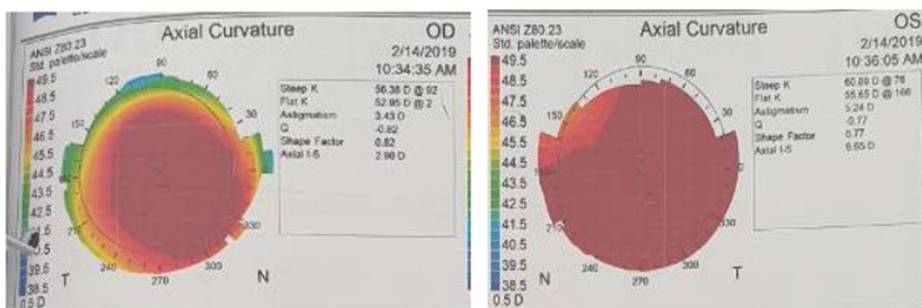


Figure 2. The corneal topography of the right (OD) and left (OS) eye.

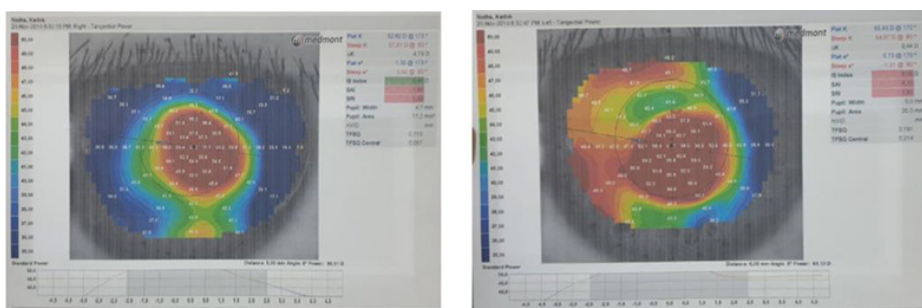


Figure 3. Corneal topography of both eyes

Eight months after surgery, the patient complained of blurry vision in both eyes. On ophthalmologic examination revealed VA of the right eye was 6/12 PH 6/9 and VA of the left eye was 6/60 and no improvement with pinhole. Anterior segment examination on both eyes found IOL and Posterior Capsular Opacification (PCO). The patient was planned for ND – Yag capsulotomy. The patient also underwent corneal topography, specular examination and anterior OCT on both eyes. The corneal topography of the right eye showed steep K 57.61 D @ 83; Flat K 52.82 D @ 173; Δ K: 4.79 D; IS index 0.81 D; SAI 1.99; SRI 1.39. The topography of the left eye is steep K 64.87 D @ 80; Flat K 55.43 D @ 170; Δ K: 9.44 D; IS index 5.05 D; SAI 4.10; SRI 1.81. The average CCT in the right eye showed a mean CCT of 444, while the mean CCT of the left eye was 387 (Figure 3).

Post-ND-YAG capsulotomy, the VA of the right eye was 6/10 PH 6/7.5, with C - 4.00 x 180° VA became 6/7.5. VA in the left eye was 6/15 PH 6/10, with C - 4.00 x 170° VA became 6/7.5. One month post-ND YAG capsulotomy, the VA of the right eye was 6/15 PH 6/6, with C - 4.00 x 180° VA became 6/6. VA left eye was 6/18 PH 6/9, with C - 4.00 x 180° VA became 6/9. Binocular vision was 6/6, comfortable with adaptation. For near vision, +3.00 was added for both eyes.

DISCUSSION

Keratoconus is a common disorder in which the central or paracentral cornea undergoes progressive thinning and protrusion, resulting in a cone-shaped cornea and leads to irregular astigmatism and visual deterioration.^{1,2}

The reported prevalence of keratoconus is highly variable, ranging from 0.0003% in Russia, 2.3% in India, to 0.054% in the USA.² A hereditary pattern is not prominent or predictable, but positive family histories have been reported in 6%–8% of cases. Genetic predisposition and environmental risk factors such as eye rubbing, inflammation, atopy, hard contact lens wear, and oxidative stress all play a role in the onset and progression of keratoconus.^{1,2}

Keratoconus could be difficult to detect in its early phase. There are

few clinical signs that could raise the clinician suspicion. Characteristic signs of Keratoconus are Rizzutti sign, a focusing of the light within the nasal limbus when a penlight is shone from the temporal side, an early but nonspecific finding. Munson sign, an inferior deviation of the lower eyelid contour on downgaze, is also a late nonspecific sign. Iron deposition within the basal epithelium at the cone base forms a Fleischer ring. Best seen with the slit-lamp using a broad, oblique beam and the cobalt-blue filter.¹ Meanwhile, Corneal topography and tomographic have been accepted as sensitive methods for early diagnosis, monitoring progression, and treatment of Keratoconus. In addition, this advanced examination also used to visualise an irregular astigmatism, improve contact lens fitting, detection of other corneal ectatic disorders, corneal degeneration, trauma, scarring, corneal surgery, corneal thickness, angle elevation cornea, epithelial imaging and analysis anterior segment.^{4,5,7}

The topographic pattern of eyes with keratoconus usually shows inferonasal or inferotemporal area of steepening in the central and the upper regions. Typically, a variation greater than 10.00 diopters between the steepest and flattest curvatures indicates keratoconus.⁵ Basically, the management of keratoconus is aimed to improve the eyes refractive power. The management includes glasses, contact lens, scleral lens, Intrastromal Corneal Ring Segments, RLE, Penetrating Keratoplasty (PK) or Deep Anterior Lamellar Keratoplasty (DALK), Corneal Cross-Linking, CXL Plus, Accelerated Cross-Linking. Keratoconus is a contraindication for LASIK and corneal surface ablation procedure. The weakening of the cornea during LASIK flap creation and tissue removal could significantly increase the risk of progressive ectasia.^{1,5,8}

RLE is the removal of the non-cataract lens with or without IOL implantation. RLE surgical technique is similar to the standard cataract surgery technique. The main element that distinguishes between RLE and standard cataract surgery is that in RLE, the crystalline lens still in its normal anatomical conditions. As in this case, a high myopia is an indication for RLE.^{9,10} Advantage of the RLE procedure

is that it can maintain the normal contour of the cornea, thus improving the quality of vision quickly and eliminating the need for cataract surgery in the future. For cases of high myopia and astigmatism, it can also be accompanied by Limbal Relaxing Incision (LRI) or implantation toric IOL.^{9,11} Disadvantage of RLE is that the patient's expectation for visual acuity is higher than patients with cataract surgery, so it is essential to provide thorough preoperative informed consent, uncorrected residual refractive errors during intraoperative IOL insertion, and postoperative care.^{11,12}

Lastly, it is important to mention that an untreated Keratoconus would likely result in deterioration of vision. The complication of keratoconus is vision loss, mainly as a result of irregular astigmatism and myopia due to corneal protrusions and corneal scarring. Corneal thinning usually occurs in the center of the cornea as well as in the inferotemporal cornea. Advanced keratoconus can develop into corneal hydrops called acute keratoconus. The Descemet layer breaks and is associated with the stromal clefts that can cause the aqueous humour to enter the stroma, causing corneal scars. Patients usually report sudden vision loss and discomfort in the eyes accompanied by pain and conjunctival injection.¹ An early detection and proper treatment is the only way to save the vision.

CONCLUSION

Keratoconus is a visual disturbance that occurs when the cornea's central or paracentral shape undergoes progressive thinning and protrusion, creating a cone-shaped cornea. Keratoconus is a contraindication for LASIK procedure and corneal surface ablation. Thus, a complete examination of the eye is essential for proper diagnosis before deciding on a specific treatment. A critical test to determine Keratoconus' presence or absence is a conventional topography to see the cornea curvature and characteristics. RLE + IOL implantation is one of the most effective and safe procedures that could be offered to treat high myopia due to Keratoconus. Additionally, a scleral lens can be added to correct irregular astigmatism so optimal vision can be achieved.

ETHICAL CONSIDERATION

The authors had gained consent from the patients to publish this case in an academic journal without revealing any personal identity and solely for educational purposes.

CONFLICT OF INTEREST

The authors stated no conflict of interest.

FUNDING

The author is independently responsible for this case report's funding without involving sponsorship or other funding sources.

AUTHORS CONTRIBUTION

All authors contributed equally in all phases of the study.

REFERENCE

- American Academy of Ophthalmology. Corneal Dystrophies and Ectasias. In: BCSC External Disease and Cornea - Section 8. San Fransisco: AAO; p. 161–8.
- Andreanos KD, Hashemi K, Petrelli M, Droustas K, Georgalas I, Kymionis GD. Keratoconus Treatment Algorithm. *Ophthalmol Ther*. 2017;6(2):245–62.
- Romero-Jiménez M, Santodomingo-Rubido J, Wolffsohn JS. Keratoconus: A review. *Contact Lens Anterior Eye*. 2010;33(4):157–66.
- American Academy of Ophthalmology. The Science of Refractive Surgery. In: BCSC Refractive Surgery. San Fransisco: AAO; p. 29–36. (2019-2020).
- Anderson D. Understanding Corneal Topography [Internet]. AOA; 2017. Available from: <https://www.aoa.org/Documents/optometric-staff/Articles/Understanding-Corneal-Topography.pdf>
- Martin R. Cornea and anterior eye assessment with placido-disc keratoscopy, slit scanning evaluation topography and scheimpflug imaging tomography. *Indian J Ophthalmol*. 2018;66(3):360–6.
- Naderan M, Jahanrad A, Farjadnia M. Clinical biomicroscopy and retinoscopy findings of keratoconus in a Middle Eastern population. *Clin Exp Optom*. 2017;101(1):46–51.
- Denny P. Keratoconus: New Consensus, New Goals - American Academy of Ophthalmology [Internet]. Available from: <https://www.aao.org/eyenet/article/keratoconus-new-consensus-new-goals?plckFindCommentKey=CommentKey:%207a532b41-52cb-405a-b378-d52edeb73ff7>
- Alió JL, Grzybowski A, Romaniuk D. Refractive lens exchange in modern practice: when and when not to do it? *Eye Vis Lond Engl*. 2014;1:10–10.
- Refractive Lens Exchange (Clear Lens Extraction) for Myopia Correction: Background, History of the Procedure, Problem [Internet]. Available from: <https://emedicine.medscape.com/article/1221340-overview>
- Srinivasan B, Leung HY, Cao H, Liu S, Chen L, Fan AH. Modern Phacoemulsification and Intraocular Lens Implantation (Refractive Lens Exchange) Is Safe and Effective in Treating High Myopia. *Asia-Pac J Ophthalmol Phila Pa*. 2016;5(6):438–44.
- Horgan N, Condon PI, Beatty S. Refractive lens exchange in high myopia: long term follow up. *Br J Ophthalmol*. 2005;89(6):670–2.



This work is licensed under a Creative Commons Attribution