



Published by DiscoverSys

## Annular pancreas in two cases after diamond-shaped anastomosis duodenoduodenostomy: case reports



CrossMark

Ni Luh Gede Wahyuni Suismaya<sup>1\*</sup>, I Made Kardana<sup>1</sup>, Kadek Deddy Ariyanta<sup>2</sup>

### ABSTRACT

**Background:** Annular pancreas is an infrequent congenital disorder characterized as a partial or complete pancreatic tissue around the descending part of the duodenum. Prenatal control is essential in the early detection of the annular pancreas. Initial management might increase better prognosis. We report two cases of the annular pancreas in Sanglah General Hospital, Denpasar, Bali in 2016-2019 to describe the clinical characteristics and outcome of different ages in annular pancreas managed by diamond-shaped duodenoduodenostomy.

**Case Description:** The first case was a six days old baby boy with bile stained vomiting every time he breastfed when she was three days old and got worsen. USG fetal showed polyhydramnios with duodenal or jejunal stenosis. Besides, the abdominal X-ray showed double bubble sign and the laboratory findings were in a standard limit. The second case was a nine months old girl with bile-stained

vomiting when she was eight months old and got worsen along with the time. She found with severe malnutrition and mild-moderate dehydration. The laboratory examination revealed electrolyte imbalanced, and abdominal X-ray showed double bubble sign. Postoperative to first feed was 1 day in both cases and full feed duration was 5 and 10 days. Length of stay was 16 and 25 days—both of the cases without complication after surgery.

**Conclusion:** Annular pancreas is a rare congenital malformation that manifests primarily by signs related to duodenal obstruction. Earlier identifications will help to ensure that appropriate treatment can be instigated as soon as possible. Treatment by surgical with duodenoduodenostomy procedure is a surgical technique in the treatment of annular pancreas, with the advances in neonatal intensive care, may reduce the postoperative complications and will make a better outcome.

**Keywords:** Annular pancreas, Duodenal Obstruction, Duodenoduodenostomy

**Cite This Article:** Suismaya, N.L.G.W., Kardana, I.M., Ariyanta, K.D. 2020. Annular pancreas in two cases after diamond-shaped anastomosis duodenoduodenostomy: case reports. *Intisari Sains Medis* 11 (2): 445-451. DOI: [10.15562/ism.v11i2.581](https://doi.org/10.15562/ism.v11i2.581)

### INTRODUCTION

Congenital duodenal obstruction is one of the most common anomalies in newborns affecting approximately one in 2500 to 10000 live births, and accounting for nearly half of all cases of neonatal intestinal obstruction.<sup>1</sup> Annular pancreas is a congenital disorder characterized as a partial or complete pancreatic tissue around the descending part of the duodenum.<sup>2</sup> Annular pancreas is one of the extrinsic cause of the duodenal obstruction., it was approximately 23% of congenital duodenal obstruction.<sup>1</sup> The reported incidence of the annular pancreas is 1 in 20.000 live births.<sup>3</sup>

The annular pancreas may cause constriction of the duodenum which may lead to symptoms of obstruction.<sup>4</sup> External compression by the annulus does not entirely account for the obstructive symptoms seen with the annular pancreas, as this anomaly usually features some component of intrinsic duodenal stenosis.<sup>4</sup> Despite its congenital aetiology, the annular pancreas can become symptomatic at any age, and has been well described in both children and adult. Importantly, clinical manifestation is different among the age group.

Stratified this condition into neonatal, pediatric, asymptomatic adult and symptomatic adult of the annular pancreas.<sup>2</sup> It has also been found that half of the patients with the annular pancreas, may have other associated congenital anomalies such as Down syndrome, oesophageal and duodenal atresia, malrotation, Meckel's diverticulum, pancreas divisum, imperforate anus, urogenital system abnormalities and congenital heart disease.<sup>1,2</sup>

Diagnosis of the annular pancreas usually established via radiologic imaging by evaluating a 'double-bubble' sign that is indicating a duodenal obstruction.<sup>5</sup> The annular pancreas can be diagnosed by ultrasound, which can be used to prenatal diagnosis.<sup>2,6</sup> Recently several modalities have been used to diagnose the annular pancreas.<sup>2</sup> Even this era of radiological sophistication, diagnosis may require surgical confirmation in more than 40% of the cases as each imaging modality has its limitations and need to be confirmed through surgery.<sup>7</sup>

Management of annular pancreas choice is surgical and medical management when the obstruction symptoms occur. The management adjusted to the condition of the case. Medication

<sup>1</sup>Department of Child Health, Universitas Udayana, Medical School, Sanglah General Hospital, Bali, Indonesia

<sup>2</sup>Pediatric Surgery, Universitas Udayana, Medical School, Sanglah General Hospital, Bali, Indonesia

\*Corresponding to:  
Ni Luh Gede Wahyuni Suismaya;  
Department of Child Health,  
Universitas Udayana, Medical  
School, Sanglah General Hospital,  
Bali, Indonesia;  
[niluhgedewahyuni69@yahoo.com](mailto:niluhgedewahyuni69@yahoo.com)

Diterima: 11-08-2019  
Disetujui: 03-06-2020  
Diterbitkan: 01-08-2020

and nutritional support needed. Early management improved the outcome.

Based on the mentioned above, this case study will present the experience of the Department of Child Health and Pediatric Surgery in managing some cases of the annular pancreas with different ages. Besides, this study aims to describe the clinical characteristics and outcome of different ages in annular pancreas managed by diamond-shaped anastomosis duodenoduodenostomy.

## CASE REPORTS

### First case

A six days old baby boy was brought to the emergency department of Sanglah Hospital with bile stained vomiting. She was referred from a hospital with suspicious of duodenal stenosis. He began to vomit for three days after birth. The vomiting happened every time he breastfeeds and the symptom got worsen along the time. It was profuse and projectile, about 10 times daily with bile stained vomits without blood.

The patient was the second child in the family, no history of congenital gastrointestinal anomalies in both parents nor the other siblings. No illnesses history during the pregnancy period were noted, nor a history of consuming any traditional medicine. There was polyhydramnion reported during the pregnancy and a double-bubble sign detected on ultrasound examination during the pregnancy (Figure 1) There was no history of premature rupture of membrane or cloudy green amniotic fluid. He was born vigorously with the bodyweight

of 2900 grams, and term in gestational age. He got breastmilk on demand—There were defecation and urination in 24 hours after birth.

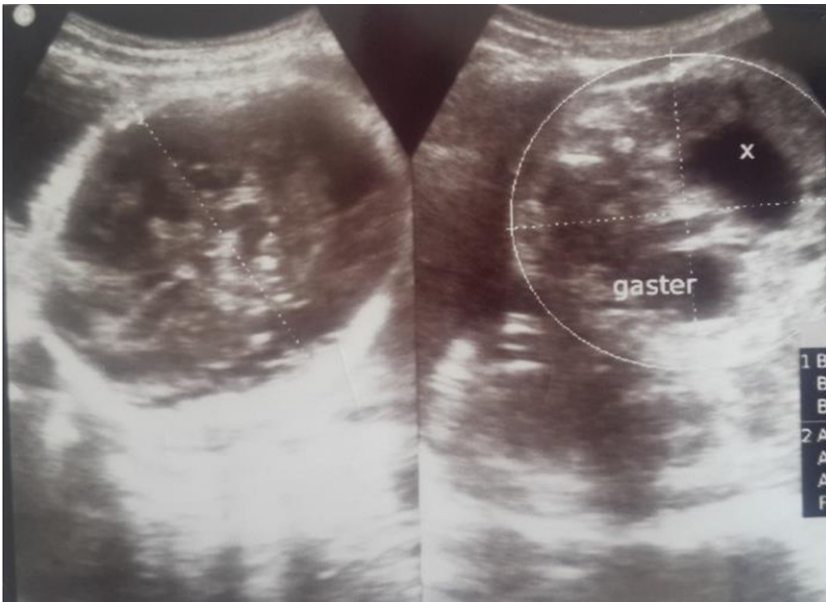Physical examination revealed patient in a weak condition, the heart rate was 140 times per minute, regular, and the respiration rate was 36 times per minute, regular. The body temperature was 36,5°C, followed by the bodyweight was 2900 grams, with body length 49 centimetres. The head circumference was 33 centimetres. The head was normal in shaped, and the hair was black, the fontanel was flat. There was no dysmorphic face. There were no jaundice on the sclera, neither conjunctiva injection and anaemia. The pupils light reflect were normal. The ear, nose, and throat examination were in a standard limit. There was no lymph nodes enlargement found on the neck. The chest was symmetrical both on rest and movement. Breath sound was broncovesicular without rales or wheezing, and the heart sound was normal, regular and no murmur in auscultation. There was no lymph nodes enlargement found on both of axillae. There was abdominal distention. The bowel sound was decreased, the liver was just palpable, and spleen was not palpable. There was no lymph nodes enlargement found on both of the inguinal regions. The extremities were normal inactivity, tonus and reflex.

The plain radiography was performed double bubble sign (Figure 2). The laboratory examination revealed WBC  $7.55 \times 10^3/\text{ul}$ , Hb 16.02 g%, thrombocyte  $243.1 \times 10^3/\text{ul}$ . IT- ratio was 0.23 and the procalcitonin was 0.19 ng/ml. The blood sugar was 92 mg/dl. Sodium 133 mmol/L, potassium 4.38 mmol/L, chloride 91.9 mmol/L, and calcium 10.8 mg/dl.

Based on clinical manifestation, laboratories finding and the plain abdominal X-ray, the differential diagnosis was suspected by duodenal stenosis differential diagnosed with duodenal web, with suspected neonatal early-onset sepsis.

The patient was given supportive therapy with total parenteral nutrition that contained with dextrose, electrolyte, protein and lipid. He had an orogastric tube for decompressing. The patient also got first-line antibiotics (ampicillin and amikacin). The patient was consulted to a pediatric surgeon for the causative therapy and planned for elective explorative laparotomy.

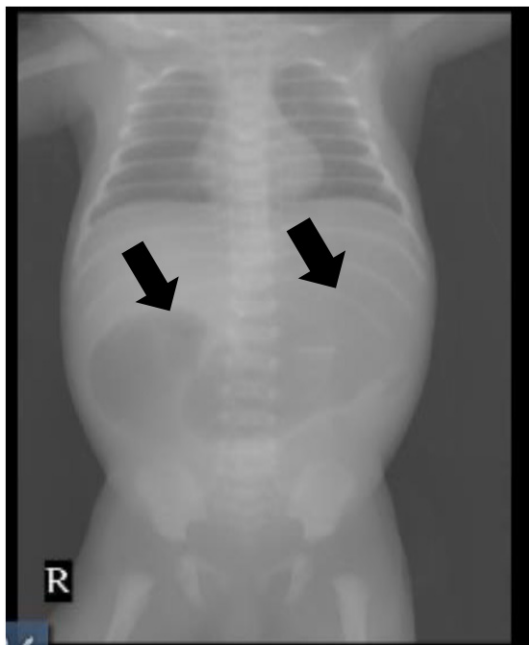
On the fifth day of care, the patient had explorative laparotomy. On the surgery site, the surgeon found the enlargement of the duodenum with the annular pancreas (Figure 3). The patient diagnosed with the annular pancreas. The patient had an incision on the stenosis part duodenum and continued with side to side anastomosis diamond shape Kimura procedure duodenoduodenostomy.



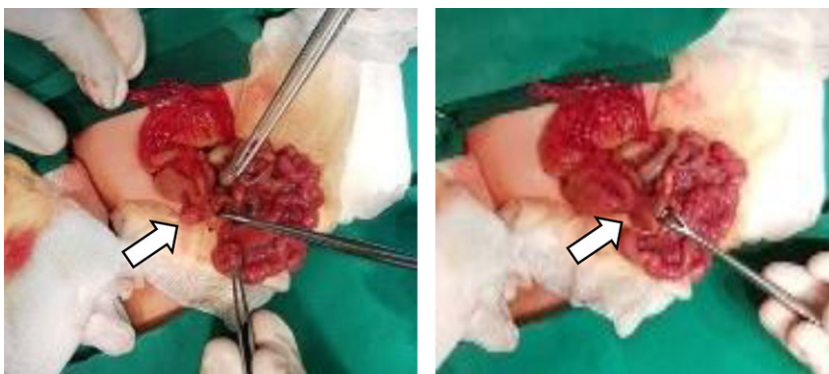
**Figure 1.** An ultrasound examination during pregnancy showed a “double bubble”.

After that, the patient was inserted feeding tube transanastomose through the proximal jejunum.

The patient was delivered to the NICU after surgery. The patient continued antibiotics therapy and total parenteral nutrition. The laboratory result after surgery was WBC  $18,03 \times 10^6/\mu\text{L}$ , haemoglobin 15,31 g/dl, thrombocyte  $208,10 \times 10^6/\mu\text{L}$ . Sodium 132 mmol/dl, potassium 5,93 mmol/dl, chloride 95 mmol/dl, calcium 10,3 mg/dl. The sixth day of treatment, the patient started the tropic feeding from the feeding tube. On the day 8<sup>th</sup>, the infection marker was improved, with WBC  $14,17 \times 10^6/\mu\text{L}$ , IT-ratio 0,03, the blood culture was no growth, and the antibiotics stopped. On the day 10<sup>th</sup>, the patient was full-fed; he tried to oral feeding and moved to neonates ward. On the day 16<sup>th</sup>, the patient was discharged in good condition with body weight was 2875 gram. Twenty-one days postoperative the patient has no symptom nor postoperative complication.



**Figure 2.** The abdominal X-ray shows double bubble sign (black arrow).



**Figure 3.** The Annular pancreas (white arrow)

### Second case

A nine months old girl was brought to the emergency department of Sanglah Hospital with bile stained vomiting and malnutrition. She was referred from the paediatrician, with suspicion of pyloric stenosis. She had no symptom until eight months old. She began to vomit and the symptom got worsen along the time. Vomiting appeared within a few hours after breastfeeding. It was profuse and projectile, 10-15 times daily with bile stained vomits without blood. The parents said weight loss occurred, but they did not know the previous body weight.

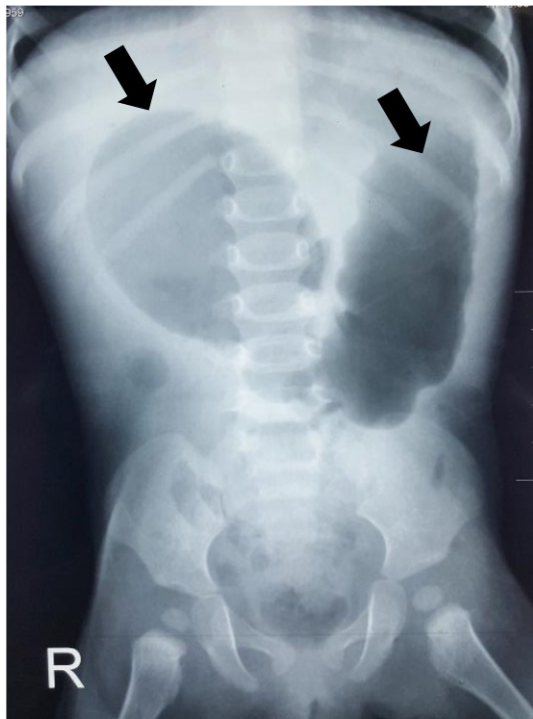
The patient was the third child in the family, no history of congenital gastrointestinal anomalies in both parents nor the other siblings. She was born vigorously with a bodyweight of 3500 grams, and term in gestational age. No illnesses history during the pregnancy period were noted, nor a history of consuming any traditional medicine. There is no abnormality during pregnancy or delivery reported such polyhydramnios reported. There is no abnormality in ultrasound examination such double bubble detected.

Physical examination revealed patient in a weak condition, the heart rate was 160 times per minute, regular, and the respiration rate was 38 times per minute, regular. The body temperature was  $38,3^{\circ}\text{C}$ . The body weight was 4 kilograms ( $<-3$  Standard deviation WHO Z-score), with body height 64 centimetres ( $<-2$  Standard deviation WHO Z-Score). The patient's ideal body weight was 6,8 kilograms (58,8% Waterlow). The head circumference was 40 centimetres ( $<-2$  Standard deviation WHO Z-score), and the arm circumference was 8 cm ( $<-2$  Standard deviation WHO Z-score). The head was normal in shaped, and the hair was black, whereas the fontanel was sunken. There were sunken eyes, but no jaundice on the sclera, neither conjunctiva injection and anaemia. The pupil light reflects normal, and there was an old man face. The ear, nose, and throat examination were in normal limit. There was no lymph nodes enlargement found on the neck. The chest was symmetric both on rest and movement. Breath sound was vesicular without rales or wheezing, and the first and second heart sound was normal, regular and no murmur in auscultation. There was no lymph nodes enlargement found on both of axilla. There was no abdominal distention, with loose abdominal skin turgor. The bowel sound was increased, liver and spleen were not palpable. There was no lymph nodes enlargement found on both of the inguinal regions. There were baggy pants, and the extremities were normal in power, tonus and reflex.

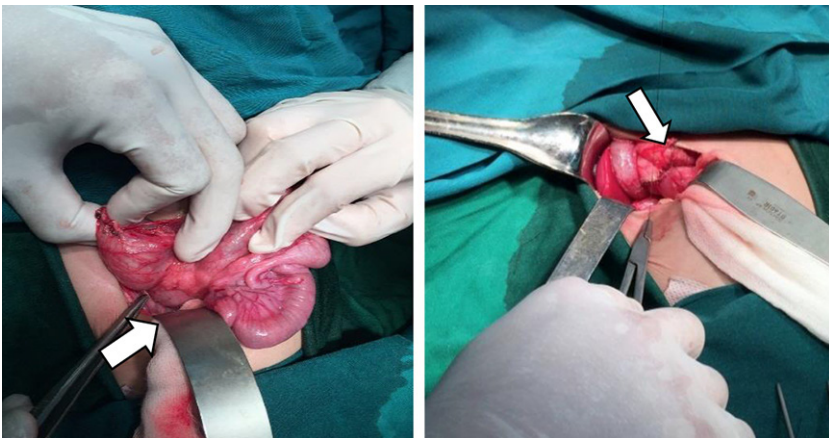
The plain abdominal X-ray was performed

and showed a double-bubble sign (Figure 4). The laboratory examination revealed electrolyte imbalanced, with sodium was 120 mg/dl, potassium 3,51 mg/dl, chloride 46,9 mg/dl and calcium 8,94 mg/dl. The blood urea nitrogen and creatinine serum increased (47 mg/dL and 1,96 mg/dL), with glomerular filtration rate 17,9 ml/minute/1,73 m<sup>2</sup>. The liver function test was within the normal limit.

Based on clinical manifestation, laboratories finding and the plain abdominal X-ray, the differential diagnosis was duodenal obstruction suspected by duodenal web, annular pancreas and malrotation with complication marasmus malnutrition, failure to thrive, acute kidney injury, electrolyte imbalance (hyponatremia) and mild-moderate dehydration.



**Figure 4.** The abdominal X-ray shows double bubble sign (black arrow)



**Figure 5.** The Annular pancreas and duodenoduodenostomy (white arrow)

The patient was hydrated using Ringer Lactate Dextrose 5% (RLD5%) 70ml/kg in ten hours. After ten hours, the patient was given total parenteral nutrition, with an orogastric tube for decompressing. The patient was consulted to a pediatric surgeon and planned for explorative laparotomy after the patient condition was stable. On the 12<sup>th</sup> day of care in a regular ward, there was an improvement in patient condition and laboratory. There was improvement for electrolyte, sodium was 136 mg/dl, potassium 3,53 mg/dl, chloride 97,3, and calcium 8,76. The blood urea nitrogen and creatinine were normal (11 mg/dl and 0,34 mg/dl), with glomerular filtration rate 103 ml/minute/1,73 m<sup>2</sup>. The patient was in optimal condition for explorative laparotomy. On the 14<sup>th</sup> day of care, the patient had explorative laparotomy. On the surgery site, the surgeon found the enlargement of the duodenum with the annular pancreas (Figure 5). The patient had an incision on the stenosis part duodenum and continued with side to side anastomosis diamond shape Kimura procedure duodenoduodenostomy, and inserted feeding tube transanastomose through the proximal jejunum.

The patient was delivered to the intermediate ward after surgery. The patient was given antibiotic therapy of intravenous ceftriaxone and total parenteral nutrition. On the day 15<sup>th</sup>, the patient started the tropic feeding from the feeding tube. On the day 18<sup>th</sup>, the patient tried to be fed from mouth according to malnutrition protocol. On the day 23<sup>rd</sup>, the patient was adequately fed and moved to a regular ward. Two days after delivered to a regular ward, the patient was discharged in good condition. Five months postoperative, the patient has no symptom nor postoperative complication. The body weight was 7,8 kilograms (<0 standard deviations WHO Z-Score), with ideal body weight 8,5 kilograms (91% Waterlow).

## DISCUSSION

Annular pancreas is a congenital disorder characterized as a partial or complete pancreatic tissue around the descending part of the duodenum.<sup>2</sup> Annular pancreas is one of the extrinsic cause of the duodenal obstruction, it was approximately 23% of congenital duodenal obstruction.<sup>1</sup> The reported incidence of the annular pancreas is 1 in 20.000 live births, affecting boys more commonly than girls.<sup>3</sup>

However, the aetiology of the annular pancreas is still widely debated. Several theories have been suggested to explain the pathogenesis, such as Lecco's theory, Baldwin's theory, and another theory.<sup>8</sup> Although various abnormalities appear to be involved in the developmental process. The annular pancreas was found in some diseased

caused by a gene mutation.<sup>3,6</sup> The familial occurrence between sibling of the congenital annular pancreas has been reported in a previous case report.<sup>9</sup> The mechanism of inheritance is not fully understood. Still, it suggested a possible dominant (autosomal or X-linked) mode of inheritance.<sup>2</sup> In our cases, the patients were six days old boy and nine months old girl, there was no history of congenital gastrointestinal anomalies in both parents nor the other siblings. However, there could be a possibility that her sibling or parents had an asymptomatic of the annular pancreas. It can be detected by radiologic examination; in this case, it was not have done.

Clinical presentation may occur at any age. Two-thirds of the cases are asymptomatic throughout their life.<sup>10</sup> However, symptomatic patients most commonly present in infancy or early childhood. Fifty percent of cases present in the pediatric age group, 86% of whom present in the neonatal period.<sup>11</sup> Conversely, the degree of obstruction may be so slight that no complaints are referable to it until subsequent years or even in adult life. The symptom may be complete or partial and cause extrinsic obstruction of the duodenum. When an annular pancreas has been productive of symptoms, it usually manifests itself in the form of acute or recurrent duodenal obstruction. Over than 40% of annular pancreas cases associated with life-threatening duodenal atresia or obstruction.<sup>2,12,13</sup> In the infant or newborn, annular pancreas appears most often in the first week of life by symptoms related to duodenal obstruction. Symptoms may appear within the early hours of life.<sup>14</sup> Signs of neonatal intestinal obstruction may initially be nonspecific including poor feeding, vomiting and irritability. If proximal of the ampulla of Vater, vomiting may be non-bilious and therefore could be confused with less severe, non-life-threatening conditions.<sup>14</sup> Children frequently present with gastrointestinal symptoms including poor feeding, vomiting and abdominal distention.<sup>12</sup> In a few geographical areas, most patients present late with malnutrition, failure to thrive, bile-stained vomiting and less frequently abdominal cramps.<sup>15</sup> In our cases, the first patient symptoms occurred at 3 days old with bilious vomiting and abdominal distention. The second case, the symptoms occurred at eight months old with bilious vomiting, mild-moderate dehydration and severe malnutrition.

There are the frequent association between annular pancreas with chromosomal anomalies and significant congenital malformation. Major congenital anomalies such complex cardiac anomalies, Hirschsprung's disease, intestinal malrotation, duodenal obstruction, Meckel's

diverticulum, imperforated anus, duodenal bands, spinal defects, cryptorchidism, Down's syndrome, can occur with the annular pancreas.<sup>2,12</sup> In our cases, there were not any congenital anomalies found.

Diagnosis of the annular pancreas usually established via radiologic imaging. Recently, several modalities have been used to diagnose the annular pancreas such as ultrasound, abdominal CT, endoscopic retrograde cholangiopancreatography (ERCP), magnetic resonance cholangiopancreatography (MRCP) and endoscopic ultrasonography (EUS).<sup>2</sup> In prenatal diagnosis can be found polyhydramnios, double bubble sign and peripancreatic hyperechogenic bands on ultrasonography that indicating a duodenal obstruction.<sup>2,6</sup> Nowadays, prenatal diagnosis of the annular pancreas is extremely rare, with only a few cases reported. However, screening efficacy for this anomaly is usually high due to characteristic finding, well visible even on old equipment of substandard quality.<sup>16</sup> In children and adults, barium studies reveal a smooth, symmetric filling defect with prestenotic dilatation of the duodenum. Even this era of radiological sophistication, the definitive diagnosis is confirmed at surgical in more than 40% of the cases as each imaging modality has its limitations.<sup>9,12</sup> A case series by Dankovcik et al., reported the following diagnostic strategy is reasonable at present. When the double-bubble sign is discovered, always suspect annular pancreas and look for the second sign: hyperechogenic bands around the duodenum.<sup>16</sup> Also look for known associated anomalies, and vice versa, if any of the related anomalies are noted, also search specifically for the signs of the annular pancreas. In our cases, the first case had polyhydramnios in prenatal history, and there was a 'double-bubble' sign in the USG of pregnancy and plain film radiography. The second case, there was no problem in pregnancy; there was a 'double-bubble' sign found in radiologic imaging—both of the diagnosis of the cases confirmed by the surgical.

Annular pancreas occurs as high intestinal obstruction. High intestinal obstruction defines as occurring proximal to the ileum with differential diagnosis and radiographic appearance as gastric atresia, duodenal atresia, malrotation, duodenal web, annular pancreas, pre duodenal portal vein, jejunal atresia.<sup>7</sup>

Gastric decompression and correction of any fluid and electrolyte disorders are the mainstays of medical management prior to surgical repair.<sup>17</sup> Surgical is both the best diagnostic modality and treatment for annular pancreas, especially that with duodenal obstruction symptom.<sup>18</sup> The surgical management is done with bypass techniques

(duodenojejunosomy, gastrojejunosomy and duodenoduodenostomy), this is because the histological examination reveals there is pancreatic tissue in duodenal muscularis.<sup>19</sup> This management is to establish the food transit to the jejunum. Duodenoduodenostomy is more physiological, so a “diamond-shaped anastomosis” may be the best alternative procedure.<sup>19</sup> Resection of the annular tissue associated with complication such as pancreatitis and pancreatic fistula.<sup>6,12,20</sup> Postoperative care involves continued gastric compression and intravenous fluid replacement.<sup>17</sup> The use of a transanastomotic feeding tube decreases not only postoperative time to initiation of enteral nutrition, but also the time to full enteral nutrition delivered proximal to the anastomosis.<sup>1,6,21,22</sup> Transanastomotic feeding tube reduces the recovery time. In our cases, both of the patients get gastric decompression and treated with fluid and electrolyte management. Intraoperative findings revealed the enlargement of the duodenum with the annular pancreas, and the patients were done with side to side anastomosis duodenoduodenostomy. The first case was adequately fed within 5 days, the second case full-fed within 9 days. There was no prematurity, congenital heart diseases or intestinal malrotation. The patients were discharged from the hospital on postoperative days thirteenth and days eleventh, with good conditions.

Surgical treatment of annular pancreas has an excellent prognosis as long as there is sufficient appropriate perioperative and postoperative care.<sup>21,22</sup> Severe outcome may present associated congenital anomaly.<sup>15</sup> A case report by Selvaraj et al. found that the mortality rates remained high after duodenoduodenostomy due to the presence of other congenital malformations and the lack of perioperative care.<sup>23</sup> Outcome after surgery has improved markedly, with early mortality rates decreasing from 83% in the 1950s to less than 10% in most recent series due to improvements in surgical techniques and advances in neonatal intensive care and anaesthesia. Deaths in contemporary series are usually attributed to severe associated congenital anomalies.<sup>23</sup> In the presence of annular pancreas associated with obstructive jaundice, biliary bypass with choledochenterostomy or placement of an internal stent may be necessary to relieve the obstruction.<sup>23</sup> In our cases, there were no congenital anomalies, and the patients were in good conditions after the duodenoduodenostomy procedure.

### CONFLICT OF INTEREST

There is no conflict of interest regarding the manuscript.

### FUNDING

This case report was self-financing without the involvement of grant, scholarship, or any other resources of funding

### AUTHOR CONTRIBUTION

All of the authors are equally contribute to the study from the selecting cases, data gathering, data analysis, until reporting the results of the case studies.

### REFERENCES

- Chen QJ, Gao ZG, Tou JF, Qian YZ, Li MJ, Xiong QX, et al. Congenital duodenal obstruction in neonates: a decade's experience from one center. *World J Pediatr.* 2014;10(3):238-244.
- Etienne D, John A, Menias CO, Ward R, Tubbs RS, Loukas M. Annular pancreas: a review of its molecular embryology, genetic basis and clinical considerations. *Ann Anat.* 2012;194(5):422-428.
- Jimenez JC, Emil S, Podnos Y, Nguyen N. Annular pancreas in children: a recent decade's experience. *J Pediatr Surg.* 2004;39(11):1654-1657.
- Pansini M, Magerkurth O, Haecker FM, Sesia SB. Annular pancreas associated with duodenal obstruction. *BMJ Case Rep.* 2012;2012:bcr2012006855.
- Piglia EBMD, Penna CRR, Tobias J, Oliveira D, Marchiori E. The main radiologic findings in annular pancreas. *Radiol Bras.* 2019;52(4):275-276.
- Li B, Chen WB, Wang SQ, Wang YB. Laparoscopic diagnosis and treatment of neonates with duodenal obstruction associated with an annular pancreas: report of 11 cases. *Surg Today.* 2015;45(1):17-21.
- Vinocur DN, Lee EY, Eisenberg RL. Neonatal intestinal obstruction. *AJR Am J Roentgenol.* 2012;198(1):W1-W10.
- Kamisawa T, Yuyang T, Egawa N, Ishiwata J, Okamoto A. A new embryologic hypothesis of annular pancreas. *Hepatogastroenterology.* 2001;48(37):277-278.
- Lainakis N, Antypas S, Panagidis A, Alexandrou I, Kambouri K, Kyriazis, et al. Annular pancreas in two consecutive siblings: an extremely rare case. *Eur J Pediatr Surg.* 2005;15(5):364-368.
- Nagpal SJS, Peeraphatdit T, Sannapaneni SK, Sharma A, Takahashi N, Kendrick ML, et al. Clinical spectrum of adult patients with annular pancreas: Findings from a large single institution cohort. *Pancreatol.* 2019;19(2):290-295.
- Yigiter M, Yildiz A, Firinci B, Yalcin O, Oral A, Salman AB. Annular pancreas in children: a decade of experience. *Eurasian J Med.* 2010;42(3):116-119.
- Lerner A, Branski D, Lebenthal E. Pancreatic diseases in children. *Pediatr Clin North Am.* 1996;43(1):125-156.
- Gross RE, Chisholm TC. Annular Pancreas Producing Duodenal Obstruction: Report of a Successfully Treated Case. *Ann Surg.* 1944;119(5):759-769.
- Sencan A, Mir E, Günsar C, Akcora B. Symptomatic annular pancreas in newborns. *Med Sci Monit.* 2002;8(6):CR434-CR437.
- Singh SK, Agrawal DK, Suganita, Singh GN. Annular pancreas causing duodenal obstruction: a case report. *J Evolution Med Dent Sci.* 2016;5(5):296-300.
- Dankovcik R, Jirasek JE, Kucera E, Feyereisl J, Radonak J, Dudas M. Prenatal diagnosis of annular pancreas: reliability of the double bubble sign with periduodenal hyperechogenic band. *Fetal Diagn Ther.* 2008;24(4):483-490.

17. McKenna LL. Pancreatic disorders in the newborn. *Neonatal Netw.* 2000;19(4):13-20.
18. Zheng HM, Cai XJ, Shen LG, Finley R. Surgical treatment of annular pancreas in adults: a report. *Chin Med J (Engl)*. 2007;120(8):724-725.
19. Zilberstein B, Sorbello MP, Orso IR, Ceconello I. Laparoscopic duodenal-jejunal bypass for the treatment of duodenal obstruction caused by annular pancreas: description of a surgical technique. *Surg Laparosc Endosc Percutan Tech.* 2011;21(2):e60-e64.
20. Kobayashi S, Honda G, Kurata M, Okuda Y, Tsuruta K. Pancreaticoduodenectomy in portal annular pancreas: report of a case. *Surg Today.* 2013;43(8):926-929.
21. Bairdain S, Yu DC, Lien C, Khan FA, Pathak B, Grabowski MJ, et al. A modern cohort of duodenal obstruction patients: predictors of delayed transition to full enteral nutrition. *J Nutr Metab.* 2014;2014:850820.
22. Arnbjörnsson E, Larsson M, Finkel Y, Karpe B. Transanastomotic feeding tube after an operation for duodenal atresia. *Eur J Pediatr Surg.* 2002;12(3):159-162.
23. Selvaraj B, Kumaran KS, Sekar GP. Annular pancreas-a case report and review of the literature. *International Journal of Recent Trends in Science and Technology.* 2014;13(2):317-321.



This work is licensed under a Creative Commons Attribution