



INTISARI SAINS MEDIS

Published by Intisari Sains Medis

A uterine leiomyoma with the prolapse large pedunculated submucosal myoma: a case report



CrossMark

Endy Cahyono^{1*}, Teuku Mirza Iskandar¹, Ediwibowo Ambari¹,
Very Great Eka Putra¹, Lubena¹, Apdhika Kristian Trisanto²

¹Gynecologic-Oncology

Division of Obstetrics and Gynecology, Faculty of
Medicine, Universitas Diponegoro/Dr. Kariadi General
Hospital, Semarang, Central Java, Indonesia

²Obstetrics and Gynaecology Specialist

Education Program, Faculty of
Medicine, Universitas Diponegoro/Dr. Kariadi General
Hospital, Semarang, Central Java, Indonesia

*Corresponding to:

Endy Cahyono; Gynecologic-Oncology
Division of Obstetrics and Gynecology,
Faculty of Medicine Universitas Diponegoro /
Dr. Kariadi General Hospital, Semarang, Central Java,
Indonesia.

endyampoeh@yahoo.co.uk

Received: 2023-02-28

Accepted: 2023-04-02

Published: 2023-04-30

ABSTRACT

Introduction: Leiomyoma is a benign tumor that originates from the smooth muscle cells of the uterus and is one of the most common tumors in women. Sometimes, this tumor can become very large and even stick out of the vagina, which is called prolapse pedunculated myoma. Having a large fibroid with prolapse myoma that protrudes out of the vagina can cause problems like a low blood count or anemia, infection risk, blockage of other organs, and tissue necrosis. Therefore, this condition needs a different treatment approach than other cases.

Case Report: A 50-year-old woman, P1A1, complained of bleeding from the vagina accompanied by a mass that protrudes out of the vagina, and also having an enlarged abdomen. On physical examination, the patient appears pale. Abdominal examination presence of a mass as high as the umbilicus. On a gynecological examination, Fluxus was found. In the vagina, there is a blue-black mass the size of a fist coming out of

it. Hemoglobin examination obtained a result of 10.2 gr/dl. Gynecologic ultrasound examination showed the uterus with a size of more than 9.42 x 15.68 x 13.27 cm, a positive endometrial thickening, and there also appeared a hyperechoic mass with a size of 7.38 x 8.11 cm. Abdominal MSCT examination using contrast showed enlargement of the uterus with solid inhomogeneous mass and intramural calcification. There is also a mass and cervical prolapse to the perineum, mild hydronephrosis, and right proximal hydroureter. It is also found multiple lymphadenopathies in paraaortic and common iliac lymph nodes. The patient then decided to perform a total abdominal hysterectomy.

Conclusion: Total abdominal hysterectomy is one of the procedures that can be done on patients who are experiencing symptoms, such as bleeding caused by a large leiomyoma size and the presence of prolapse pedunculated submucosal myoma.

Keywords: leiomyoma, prolapse pedunculated submucosal myoma, total abdominal hysterectomy.

Cite This Article: Cahyono, E., Iskandar, T.M., Ambari, E., Putra, V.G.E., Lubena., Trisanto, A.K. 2023. A uterine leiomyoma with the prolapse large pedunculated submucosal myoma: a case report. Intisari Sains Medis 14(1): 412-415. DOI: 10.15562/ism.v14i1.1690

INTRODUCTION

Uterine fibroids or leiomyomas are the most common benign tumors in women.¹ Fibroids originate from uterine smooth muscle cells (myometrium) whose growth depends primarily on estrogen levels in circulation.¹ Leiomyoma is diagnosed in nearly 70% of women with white skin and more than 80% in black women over the age of 50, but the incidence of clinical symptoms in white people is twice as high as in whites.² The economic impact of this fibroid tumor is quite extensive, affecting

about 11 million women and costing about 34 billion dollars in the United States each year.^{3,4}

Leiomyomas are classified based on their location in the uterus i.e. subserous, intramural, and submucosal. A pedunculated myoma is a form of submucosal myoma with a peduncular in the uterine cavity, that spreads to the cervix and protrudes into the introitus vagina, through the cervical canal.^{5,6} Patients who come with masses coming out of the vagina are at risk of becoming infected and having necrosis, so a different approach

is needed in the treatment of leiomyoma with pedunculated myoma. Recent studies have highlighted the significant burden of a leiomyoma on women's health that women with leiomyoma had a higher risk of preterm delivery and postpartum hemorrhage compared to women without leiomyoma.⁷⁻⁹ In this report, it will be presented patients with anemia and hydronephrosis due to leiomyoma found along with the prolapse pedunculated submucosal myoma and was decided to be performed a total abdominal hysterectomy.

CASE REPORT

A 50-year-old woman, P1A1, complained of vaginal bleeding seven days before admission and accompanied by a mass that protrudes out of the vagina. The patient had a palpable mass for 7 years but did not seek medical attention, she also experienced urinary leakage especially

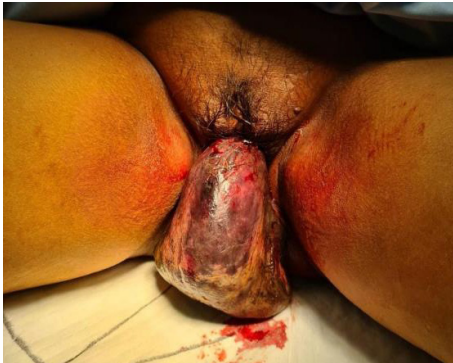

Figure 1. A fist-sized blue-black mass protruding from the vaginal introitus

when coughing and sneezing. She previously received a transfusion of 4 units of packed red blood cells.

The patient has a good general status with alert consciousness. The vital signs are as follows: blood pressure of 150/88 mmHg, heart rate of 88 bpm, respiratory rate of 21 bpm, temperature of 36.5°C, and oxygen saturation of 98% on room air.

Physical examination showed the presence of pale conjunctiva. Abdominal examination showed a presence of a mass as high as the umbilicus and a uterus with the size of a 7-month pregnancy and limited mobility. On a gynecology examination, Fluxus was found. In the vagina, there is a blue-black mass the size of a fist coming out of it. The portio was difficult to assess and elicited tenderness or pain on palpation, the size of the uterus was as large as a 7-month-old pregnant with limited mobility. The results of laboratory examinations showed mild anemia with hemoglobin levels of 10.2 g/dl.

Gynecological ultrasound examination showed a uterus with a size of more than 9.42 x 15.68 x 13.27 cm, a positive endometrial thickening, and there also appeared a hyperechoic mass with a size of 7.38 x 8.11 cm, no vascularity found in the mass.

Abdominal MSCT examination using contrast showed enlargement of the uterus with solid inhomogeneous mass and intramural calcification (largest size \pm AP 13.5 x LL 19.9 x CC 28.4 cm). There is also a mass and cervical prolapse to the perineum (size \pm 13.1 x 7.1 x 7.1 cm), mild hydronephrosis, and right proximal hydroureter. It is also found multiple lymphadenopathies in paraaortic and common iliac lymph nodes (largest size \pm 1.5 x 0.88 cm in the left common iliac lymph nodes).

In the Emergency Department, the patient received IV fluid resuscitation with 20 mL/kg of lactated Ringer's solution, IV tranexamic acid 500 mg every 8 hours, and IV ranitidine 50 mg every 12 hours, and then it was decided to perform a total abdominal hysterectomy.

DISCUSSION

Leiomyoma is a non-malignant neoplasm of the female reproductive tract that affects women in their reproductive years and causes significant symptoms and complications that impair their well-being.¹⁰ These tumors are rare in the adolescent population (under the age of 20 years) and 30-40% occur in women over 40 years of age.^{10,11} The etiology of leiomyoma is generally still not known, but the growth of this tumor is associated with the presence of a response to the stimulus of estrogen and progesterone, so its prevalence increases throughout reproductive age and decreases after menopause.¹¹ Although the precise cause of leiomyoma is unknown, it is thought to be impacted by several hormonal and genetic factors. Women who have never been pregnant are likely to have a higher risk of developing leiomyoma than those who have had children. The risk also rises with age and parity. Additional possible risk factors include being obese, having a family history of leiomyoma, and having certain diseases like diabetes and hypertension.

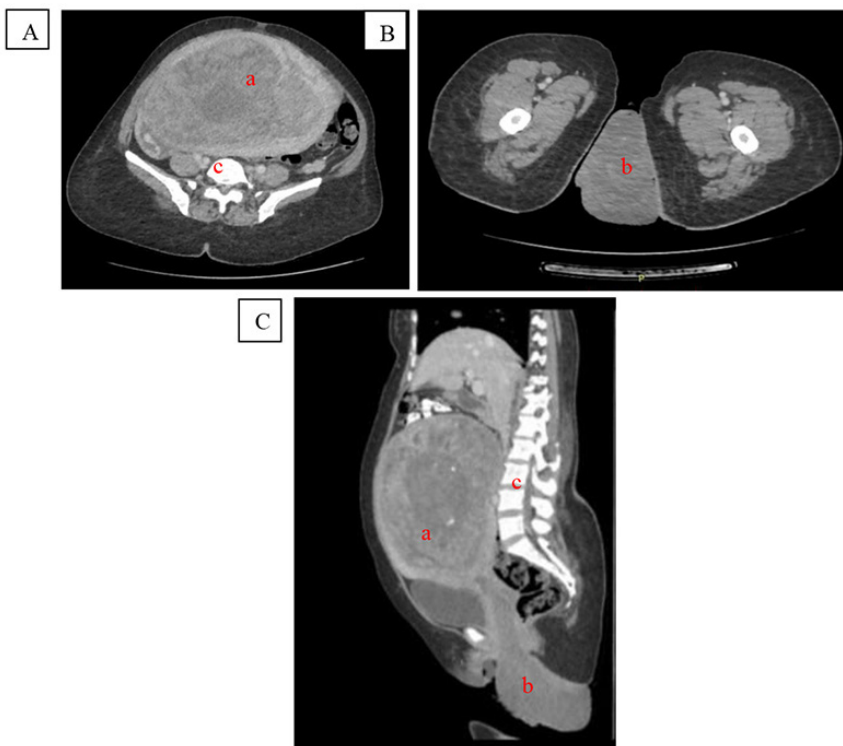


Figure 2. Abdominal MSCT in contrast appears to be an enlarged uterus with solid inhomogeneous mass and intramural calcification accompanied by a mass and cervical prolapse to the perineum
NB: (A). transverse plane on pelvic level, (B). transverse plane on thigh level, (C). Sagittal plane, (a). Uterus, (b). Prolapse protruded Mass, (c). vertebrae

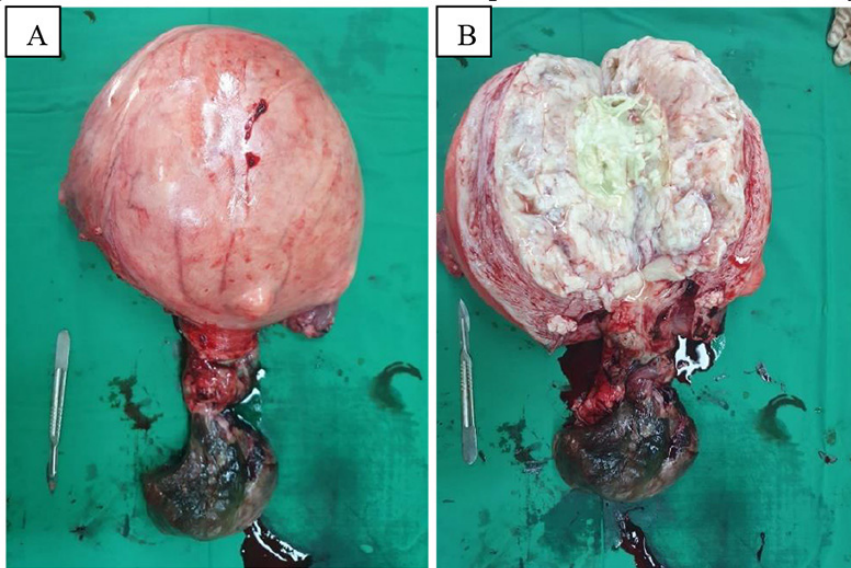


Figure 3. The postoperative specimen revealed a large uterine leiomyoma
NB: A. Uterine and mass compared with a surgical scalpel, B. Cut a section of uterine and mass

When submucosal myoma undergoes lengthening and dilation to the endocervical canal, it will cause myoma to descend into the vagina due to its heavy weight and will contribute to pulling down the uterus, bladder, vaginal wall, and cause lengthening of the cervix. This condition can cause uterine prolapse, even up to the occurrence of uterine inversion.¹² Patients with prolapse pedunculated submucosal myoma have common symptoms such as abnormal uterine bleeding, anemia, discharge, lower abdominal pain, heaviness and distress of the pelvis, urinary incontinence, constipation to reproductive dysfunction.¹² The presence of a long pedicle also causes inadequate blood circulation that passes through the pedicle it can cause necrotic infection, and if the pedicle experiences a twist, it will cause an infarction, redness, and bleeding to the occurrence of necrosis.⁵ This patient with symptoms of vaginal mass and abnormal uterine bleeding, underlies the cause of anemia or the decrease of hemoglobin level accompanied by a pale appearance.

The management of patients with uterine leiomyoma depends on the age of the patient and family planning goals and also depends on the size of the tumor and its symptoms. In patients who do not show any symptoms, they are still observed

and carried out regularly evaluations to dismiss the possibility of malignant changes.¹³ Meanwhile, in symptomatic patients, surgical treatments such as myomectomy, myolysis, and hysterectomy can be performed. Differentiation of myomectomy is often performed on young patients who still want to preserve fertility while hysterectomy is often performed for women with symptomatic leiomyoma who do not want to maintain their fertility.^{14,15} In patients, a total abdominal hysterectomy is performed because this is due to the large size of the fibroids, and the symptoms complained by the patient, bleeding, urinary incontinence, and fibroids that protrude from the vaginal introitus, other considerations are also age factors and the desire of patients who do not want to maintain their fertility.^{16,17}

One of the strengths of a case report is describing the patient's disease and treatment in detail, which can be helpful to physicians dealing with similar cases. Nonetheless, as it just reflects one case, it is limited in that it cannot prove causation or generalize results to a larger population.¹⁸

CONCLUSION

Total abdominal hysterectomy is one of the procedures that can be done on patients who are experiencing symptoms, such as

bleeding caused by a large leiomyoma size and the presence of prolapse pedunculated submucosal myoma.

ACKNOWLEDGEMENT

This study was assisted by the Department of Obstetrics and Gynecology, Faculty of Medicine, Diponegoro University.

CONFLICT OF INTEREST

The author reports no conflicts of interest in this work

ETHICS APPROVAL

Permission has been approved by the patient and the head of the Gynecologic-Oncology Division of Obstetrics and Gynecology, Faculty of Medicine, Universitas Diponegoro /Dr. Kariadi General Hospital, Semarang for using the information in this case report.

FUNDING

This case report was funded by the authors

AUTHOR CONTRIBUTION

All authors contributed equally to the writing of this article

REFERENCES

1. Barjon K, Mikhail LN. Uterine Leiomyomata. [Updated 2021 Aug 11]. In: StatPearls [Internet]. Treasure Island (FL): StatPearls Publishing; 2021 Jan-.
2. Stewart EA, Laughlin-Tommaso SK, Catherino WH, Lalitkumar S, Gupta D, Vollenhoven B. Uterine fibroids. *Nat Rev Dis Primers*. 2016 Jun 23; 2:16043.
3. Marsh EE, Al-Hendy A, Kappus D, Galitsky A, Stewart EA, Kerolous M. Burden, Prevalence, and Treatment of Uterine Fibroids: A Survey of U.S. Women. *J Womens Health (Larchmt)*. 2018 Nov;27(11):1359-1367.
4. Cardozo ER, Clark AD, Banks NK, Henne MB, Stegmann BJ, Segars JH. The estimated annual cost of uterine leiomyomata in the United States. *Am J Obstet Gynecol*. 2012 Mar;206(3): 211.e1-9.
5. Thompson JD, Rock JA (2003) Leiomyomata uteri and myomectomy. In: Te Linde's text book operative gynecology,(9th edn). Lippincott-Raven, New York, USA. pp 256-261.
6. Yang J-H, Chen M-J, Chen C-D, Chen C- L, Ho H-N, Yang Y-S. Impact of submucosal myoma on the severity of anemia. *Fertil Steril*. 2011 Apr;95(5):1769-1772.e1.
7. Faivre E, Surroca MM, Deffieux X, Pages F, Gervaise A, et al. (2010) Vaginal myomectomy:

- literature review. *J Minim Invasive Gynecol* 17: 154-160.
8. Hasanuddin, Hendryan D. The similarity of a desmoid tumor with parasitic leiomyoma: a very rare case report and literature review. *Bali Medical Journal*. 2022;11(1):77-80.
 9. Yeni CM, Maharani CR, Supriadi H. Unexpected leiomyosarcoma after total abdominal hysterectomy with indication uterine myoma in nullipara: A case report. *Bali Medical Journal*. 2021;10(2):775-9.
 10. Sparic R, Mirkovic L, Malvasi A, Tinelli A. Epidemiology of uterine myomas: a review. *International journal of fertility & sterility*. 2016 Jan;9(4):424.
 11. Ernest A, Mwakalebela A, Mpondo BC. Uterine leiomyoma in a 19-year-old girl: Case report and literature review. *Malawi Medical Journal*. 2016 Apr 6;28(1):31-3.
 12. Bezircioglu I, Sakarya DK, Yetimalar MH, Kayhan E, Yildiz A, et al., (2015) A Huge Vaginal Prolapsed Pedunculated Uterine Leiomyoma: A Case Report. *J Clin Stud Med Case Rep* 2: 005.
 13. Lumsden MA. Modern management of fibroids. *Obstet Gynaecol Reprod Med*. 2013 Mar;23(3):65-70.
 14. Falcone T, Walters MD. Hysterectomy for benign disease. *Obstet Gynecol*. 2008;111(3):753-767.
 15. Pagehgiri HD, Puruhito I, Aditiawarman, Lestari P, Sembiring YE, Jiwangga D, et al. The role of transdermal carbon dioxide on changes in malondialdehyde levels as a marker of ischemia-reperfusion injury in patients with placenta accreta spectrum underwent temporary abdominal aortic cross-clamping as an adjunct procedure during cesarean hysterectomy. *Bali Medical Journal*. 2022;11(2):1023-9.
 16. Moen M. Hysterectomy for Benign Conditions of the Uterus: Total Abdominal Hysterectomy. *Obstetrics and gynecology clinics of North America*. 2016 Sep 1;43(3):431-40.
 17. Vilos GA, Allaire C, Laberge PY, Leyland N, Vilos AG, Murji A, Chen I. The management of uterine leiomyomas. *Journal of Obstetrics and Gynaecology Canada*. 2015 Feb 1;37(2):157-78.
 18. Neis KJ, Zubke W, Fehr M, Römer T, Tamussino K, Nothacker M. Hysterectomy for benign uterine disease. *Deutsches Ärzteblatt International*. 2016 Apr;113(14):242.



This work is licensed under a Creative Commons Attribution